ORAL PATHOLOGY

Giant cells lesions

Lab. 7

DR.NOOR

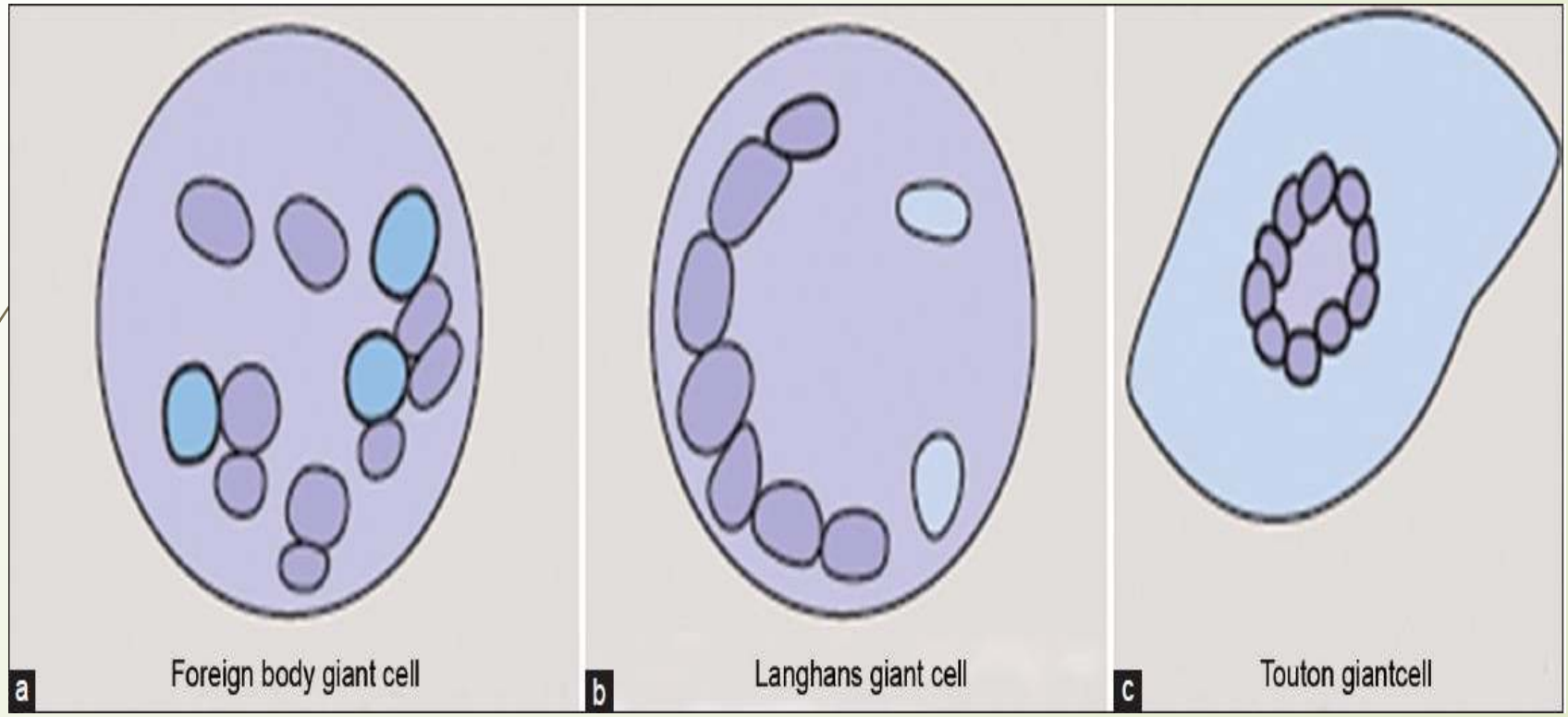
a
Foreign body giant cell
b
Langhans giant cell
c
Touton giantcell

GIANT CELL LESIONS

- 1-Giant cell granuloma (central-peripheral)
- 2-Giant cell tumor (osteoclastoma)
- 3-Aneurysmal bone cyst
- 4-Cherubism
- 5-brown tumor of hyperparathyroidism

Peripheral Giant Cell Granuloma

Nodular blue purple mass of the mandibular gingiva.

Peripheral giant cell granuloma.
Nodular reddish-purple mass of the maxillary gingiva.

Peripheral giant cell granuloma ulcerated mass of the mandibular gingiva.

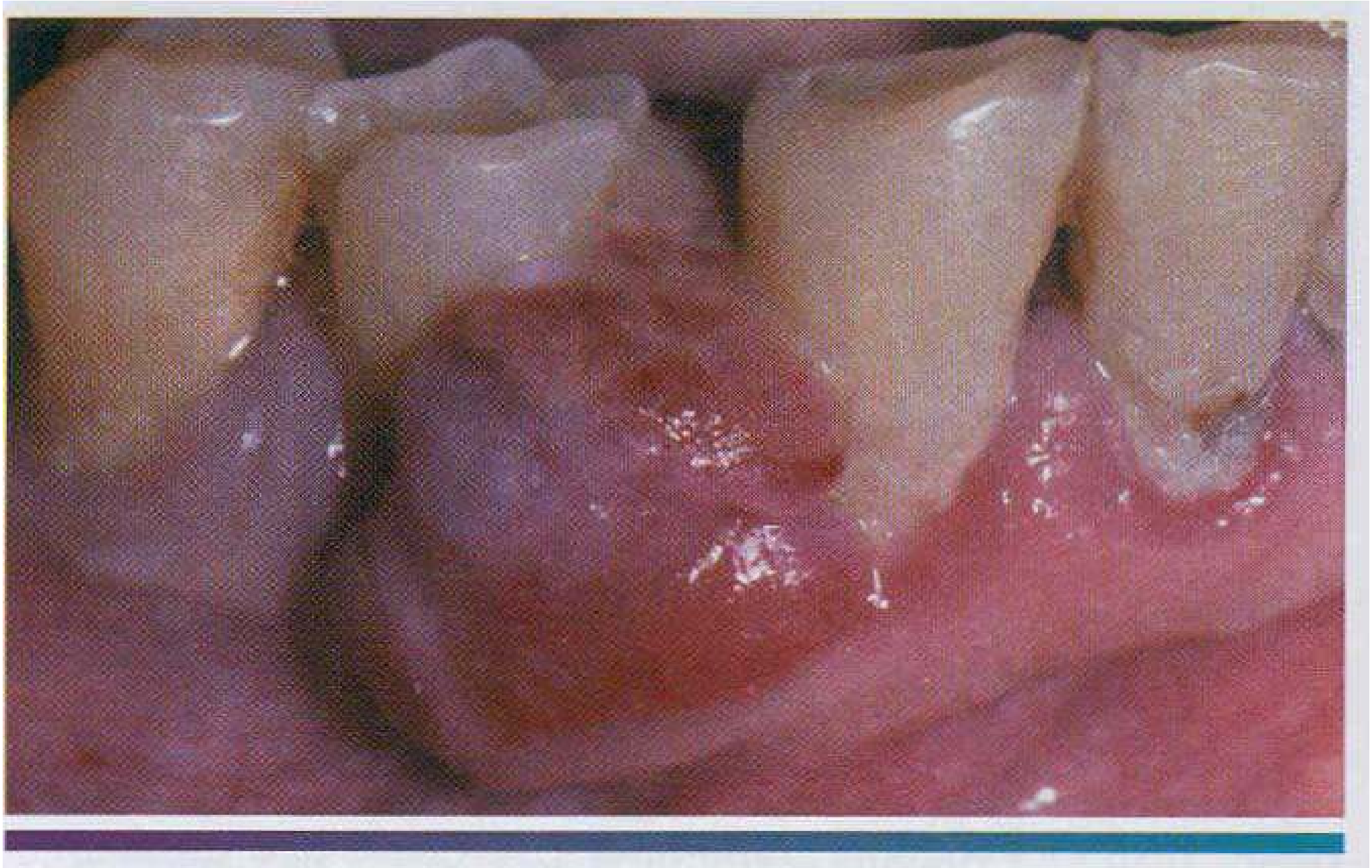

Pyogenic granuloma.

Erythematous, hemorrhagic mass arising from the maxillary anterior gingiva.

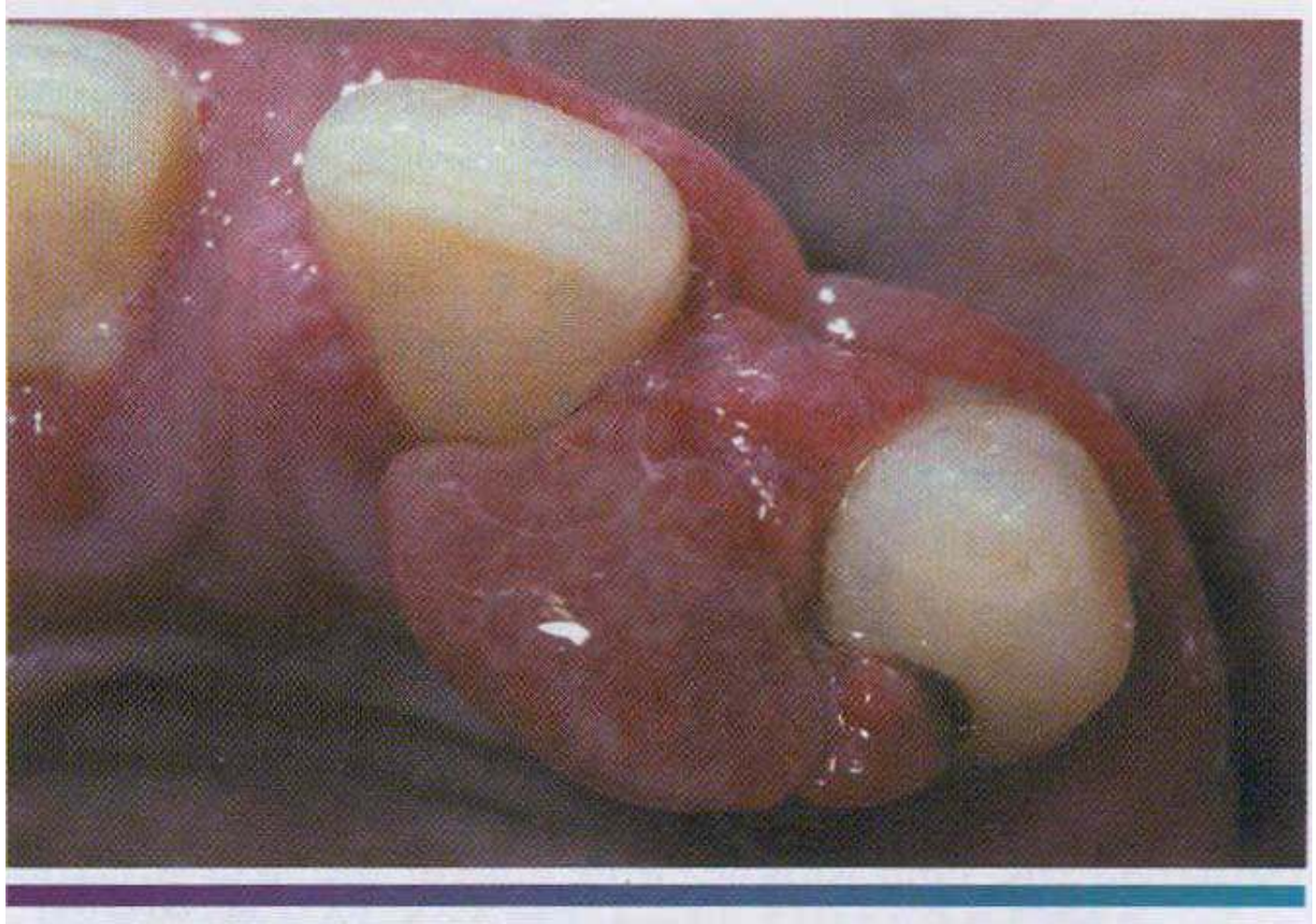

Pyogenic granuloma.
Ulcerated and lobulated mass on the dorsum of the tongue.

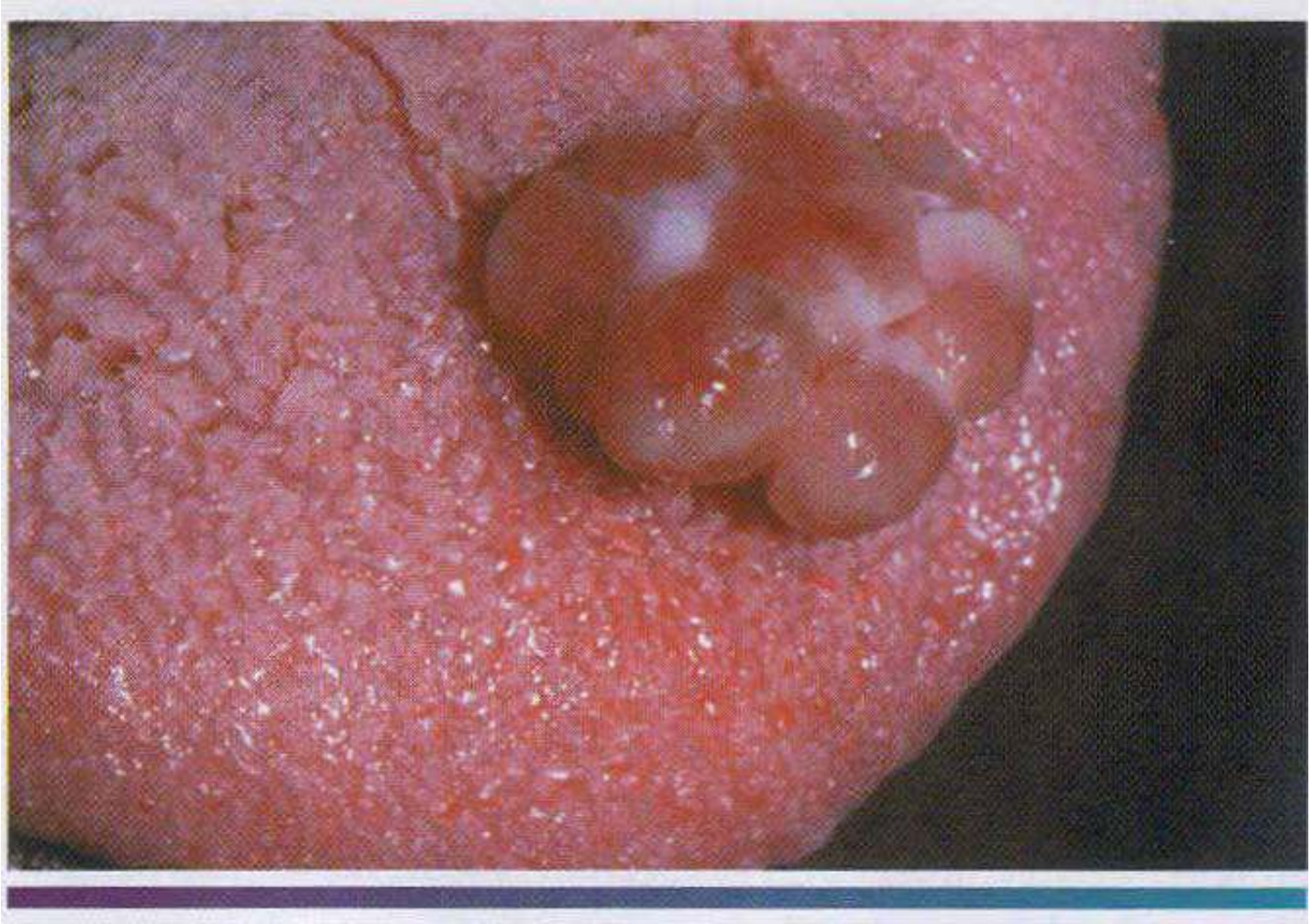

HISTOPATHOLOGIC FEATURES

- A peripheral giant cell granuloma“ shows a proliferation of multinucleated giant cells within a back ground of plump ovoid and spindle-shaped mesenchymal cells.
- The giant cells may contain only a few nuclei or up to several dozen..
- Abundant **hemorrhage** is characteristically found throughout the mass. Which often results in deposits of **hemosiderin pigment**.

- especially at the periphery of the lesion The overlying mucosal surface is **ulcerated** in about 50% of cases.
- A zone of dense **f brous connective tissue** usually separates the giant cell proliferation from the mucosal surface.
- Adjacent acute and chronic inf ammatory cells are frequently present.
- Areas of reactive bone formation or dystrophic calcifications are **not unusual**.

Peripheral giant cell granuloma. Low-power view showing a nodular proliferation of multinucleated giant cells within the gingiva.

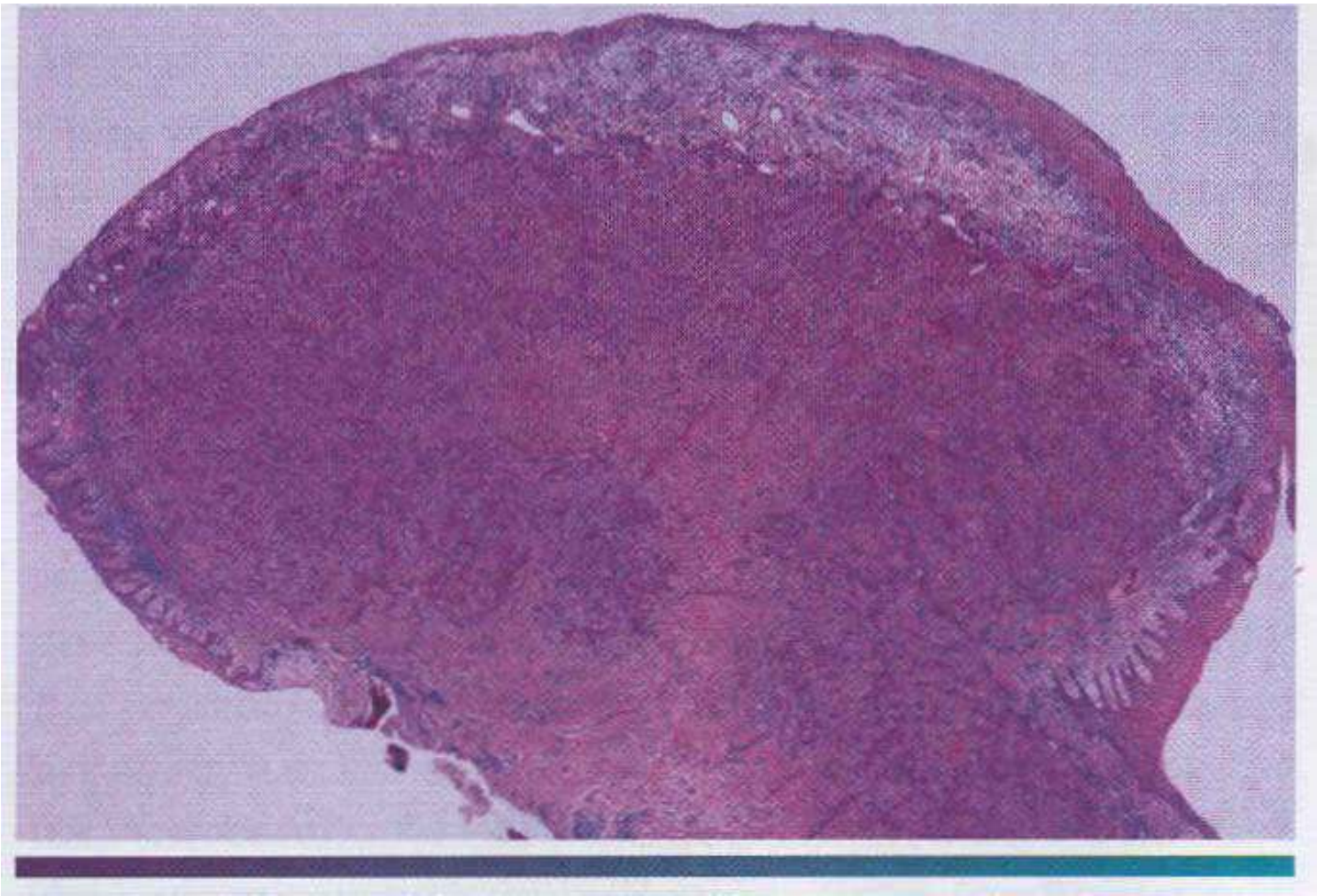

P e r i p h e r a l . g i a n t . c e l l . g r a n u l o m a
view showing scattered multinucleated giant cells within a hemorrhagic background of ovoid and spindle-shaped mesenchymal cells.

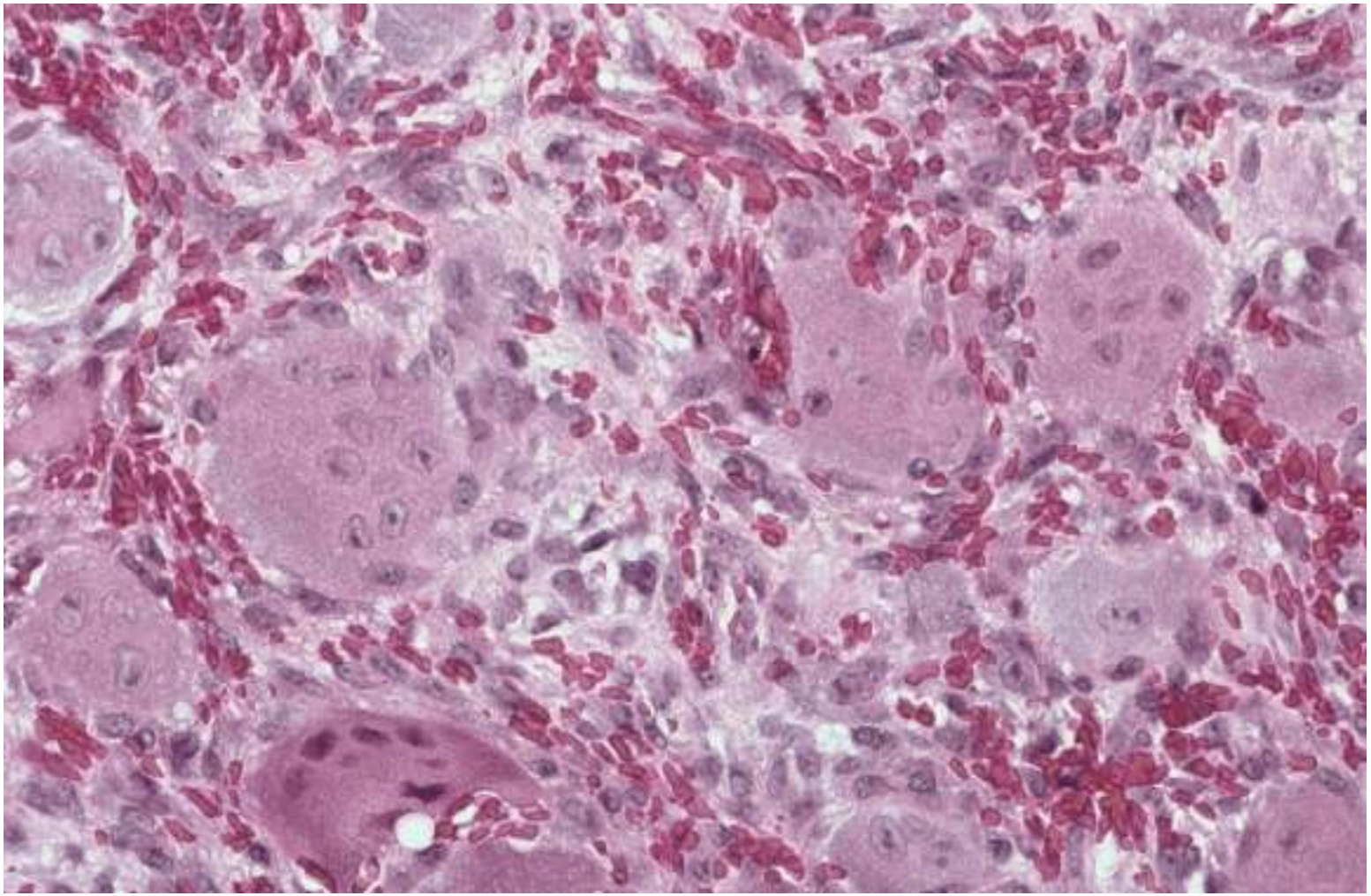

Central giant cell lesions

of the jaws may be divided into two categories:

1. Nonaggressive lesions make up most cases, exhibit few or no symptoms, demonstrate slow growth, and do not show cortical perforation or root resorption .

2. Aggressive lesions are characterized by pain, rapid growth, cortical perforation and root resorption. They show a marked tendency **to recur** after treatment,

- Radiographically, central giant cell lesions appear as radiolucent defects, unilocular or multilocular. The defect is usually well delineated, but the margins are generally non corticated.
- The lesion may vary from a 5 X 5 mm incidental radiographic finding to a destructive lesion greater than 10 cm in size. The radiographic findings are not specifically diagnostic. Small unilocular lesions may be confused with periapical granulomas or cysts .

- Because giant cell granulomas are histopathologically identical to brown tumors (hyperparathyroidism), should be ruled out in all instances.
- Most giant cell granulomas are **single lesions** rarely multifocal involvement is seen in patients who demonstrate no evidence of an associated disease, such as hyperparathyroidism or cherubism.

Central giant cell granuloma. the occlusal radiograph shows a radiolucent lesion with cortical expansion.

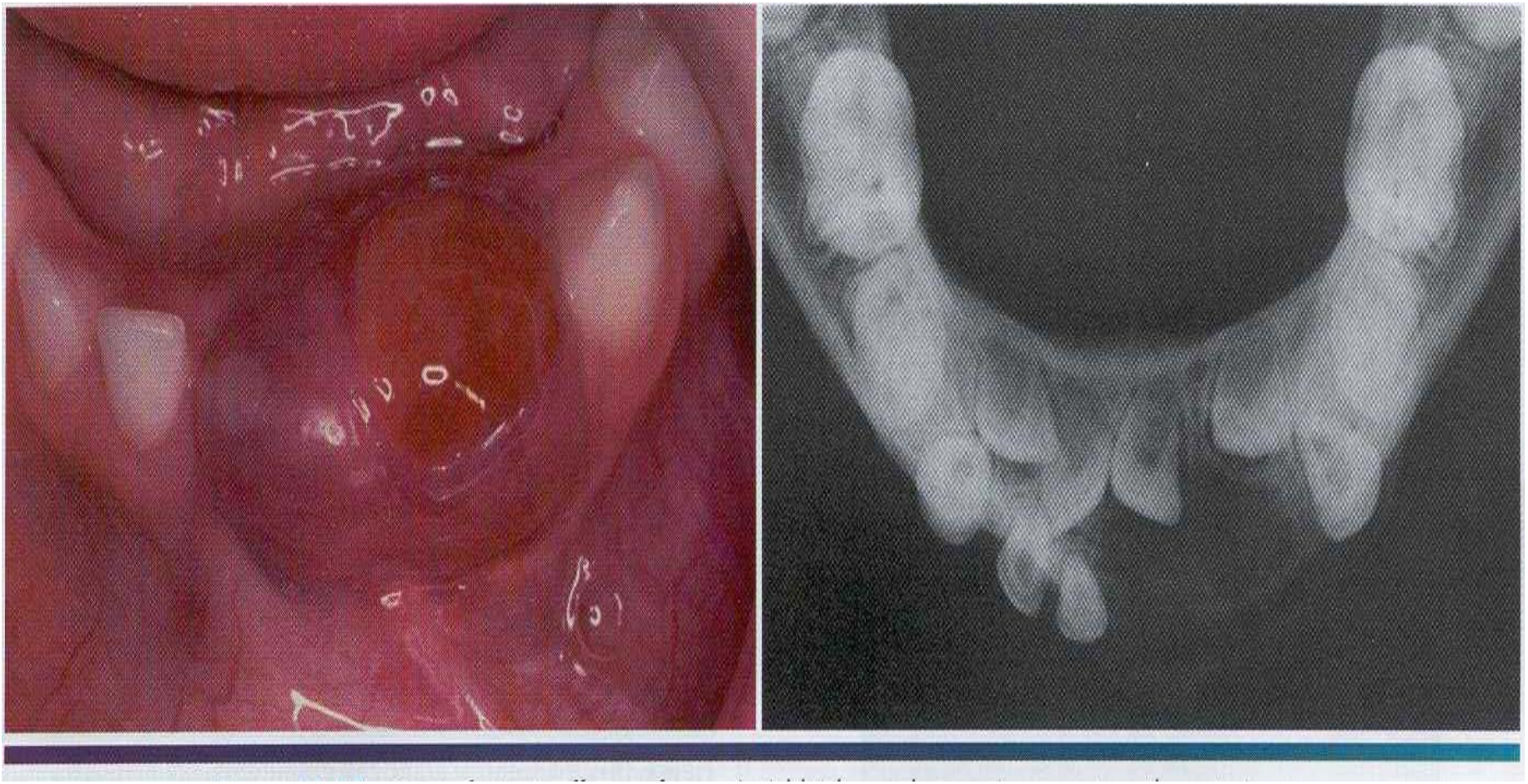

Central giant cell granuloma. A bluish-purple mass is present on the anterior alveolar ridge of this 4-year-old white boy.

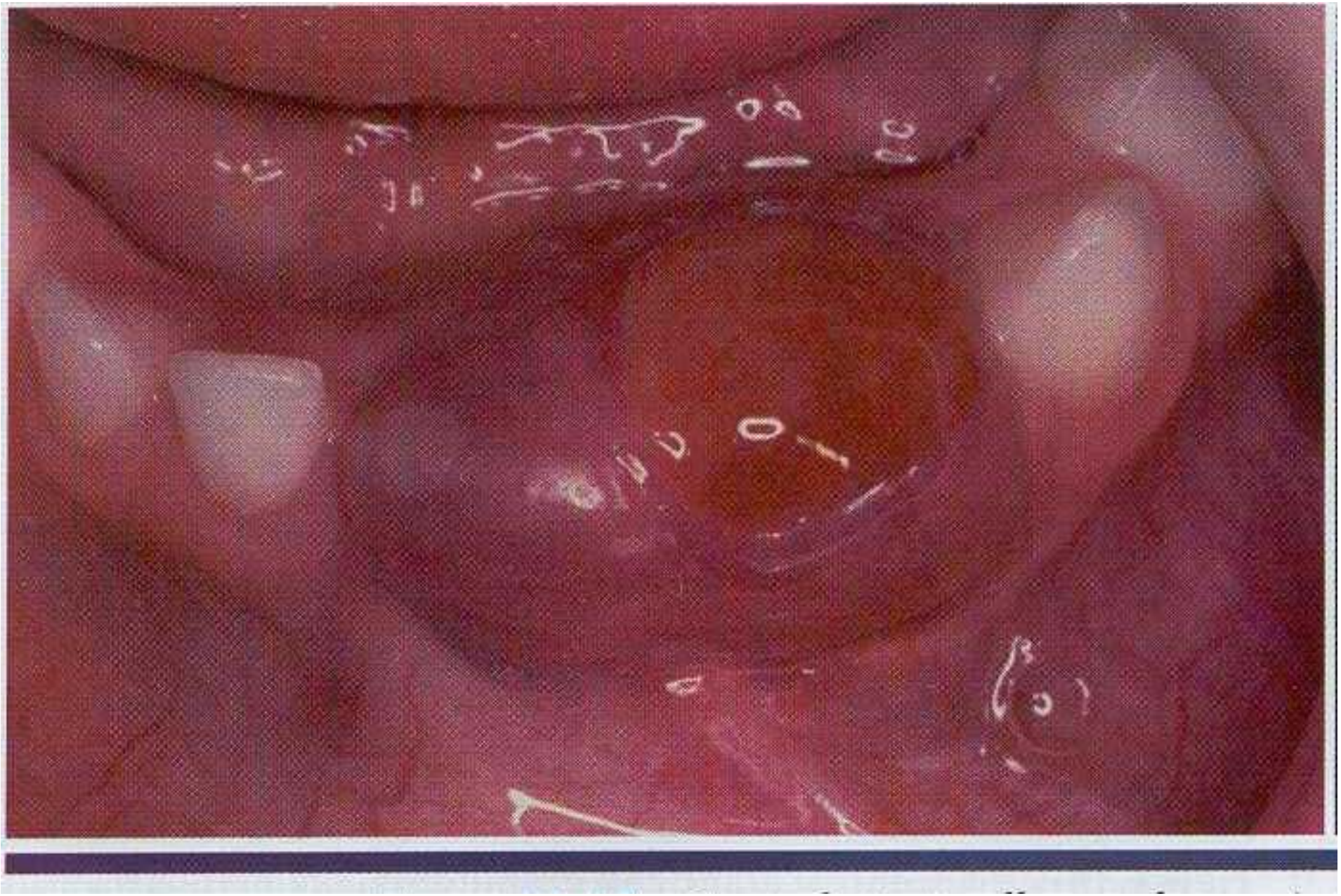

Central giant cell granuloma. Panoramic radio graph showing a large, expansible radiolucent lesion in the anterior mandible.

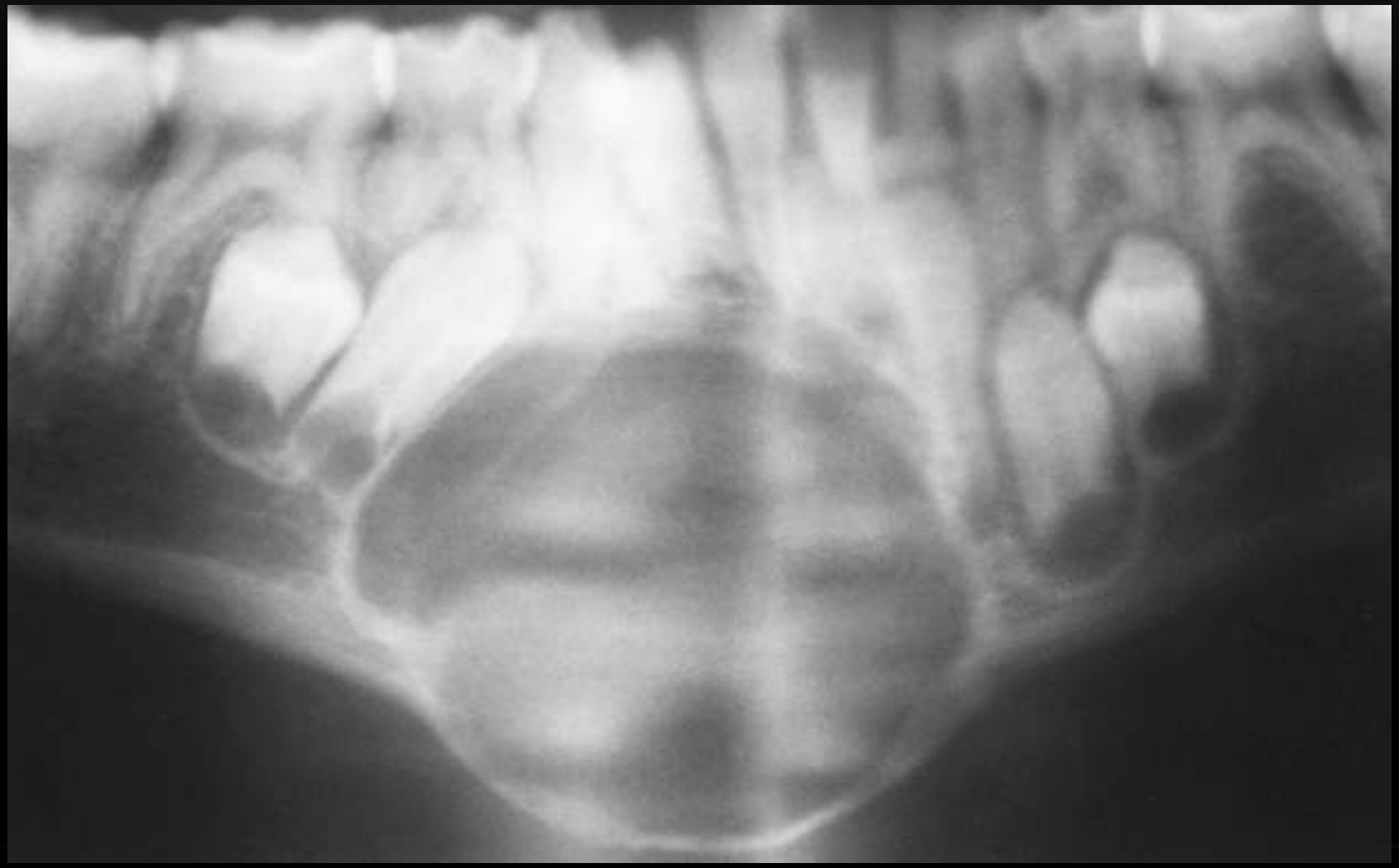

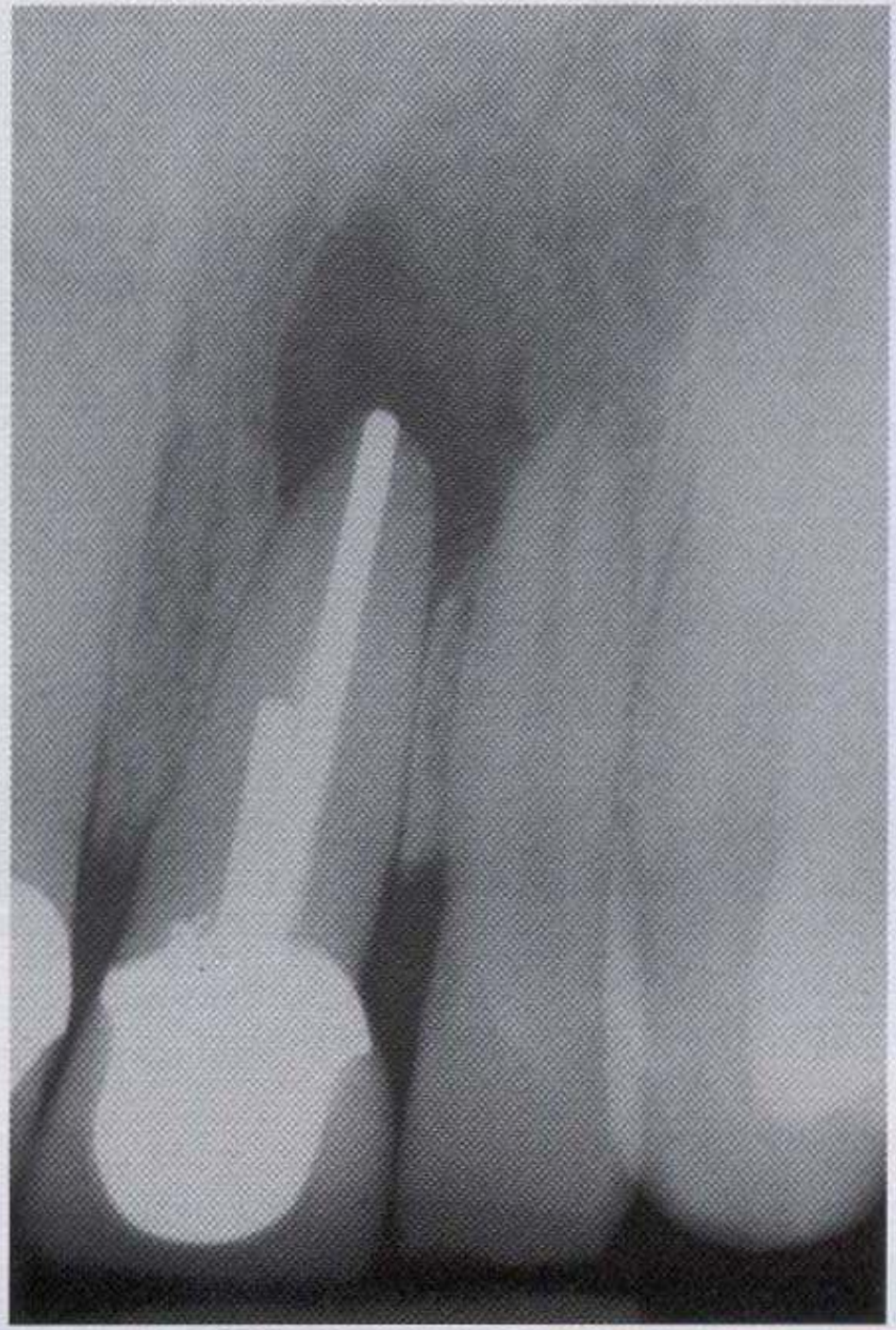

Histopathologic Features

- Few-many multinucleated giant cells in a background of ovoid to spindle shaped mesenchymal cells.
- The giant cells may be aggregated focally in the lesional tissue or may be present diffusely throughout the lesion.
- These cells vary considerably in size and shape from case to case. Some are small and irregular in shape and contain only a few nuclei. In other cases, the giant cells are large and round and contain 20 or more nuclei.

- . In some cases, the stroma is loosely arranged and edematous ,other cases; it may be quite cellular.
- Areas of **erythrocyte extravasation** and **hemosiderin** deposition often are prominent.
- Older lesions may show considerable f brosis of the stroma. Foci of osteoid and newly formed bone are occasionally present within the lesion.

- Correlation of the histopathologic features with clinical behavior remains debatable, but lesions showing large, uniformly distributed giant cells and a predominantly cellular stroma appear more likely to be clinically **aggressive** with a greater tendency to recur after surgical treatment.

Central giant cell granuloma.

Numerous multinucleated giant cells within a background of plump proliferating mesenchymal cells. Note extensive red blood cell extravasation.

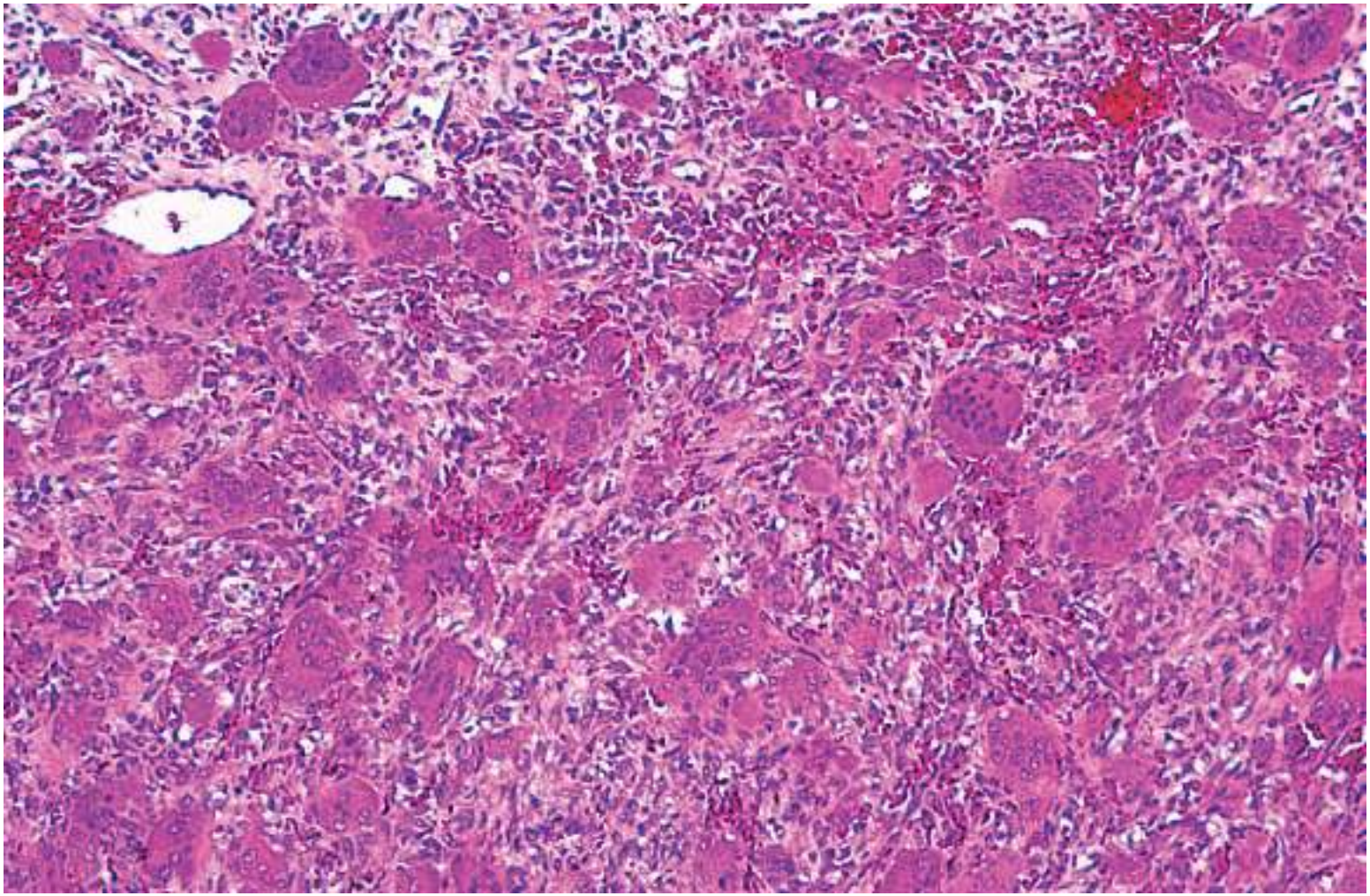

Giant cell tumor.

large giant cells that are distributed in a cellular mesenchymal tissue.

This specimen was from an aggressive lesion that had destroyed most of the maxilla.

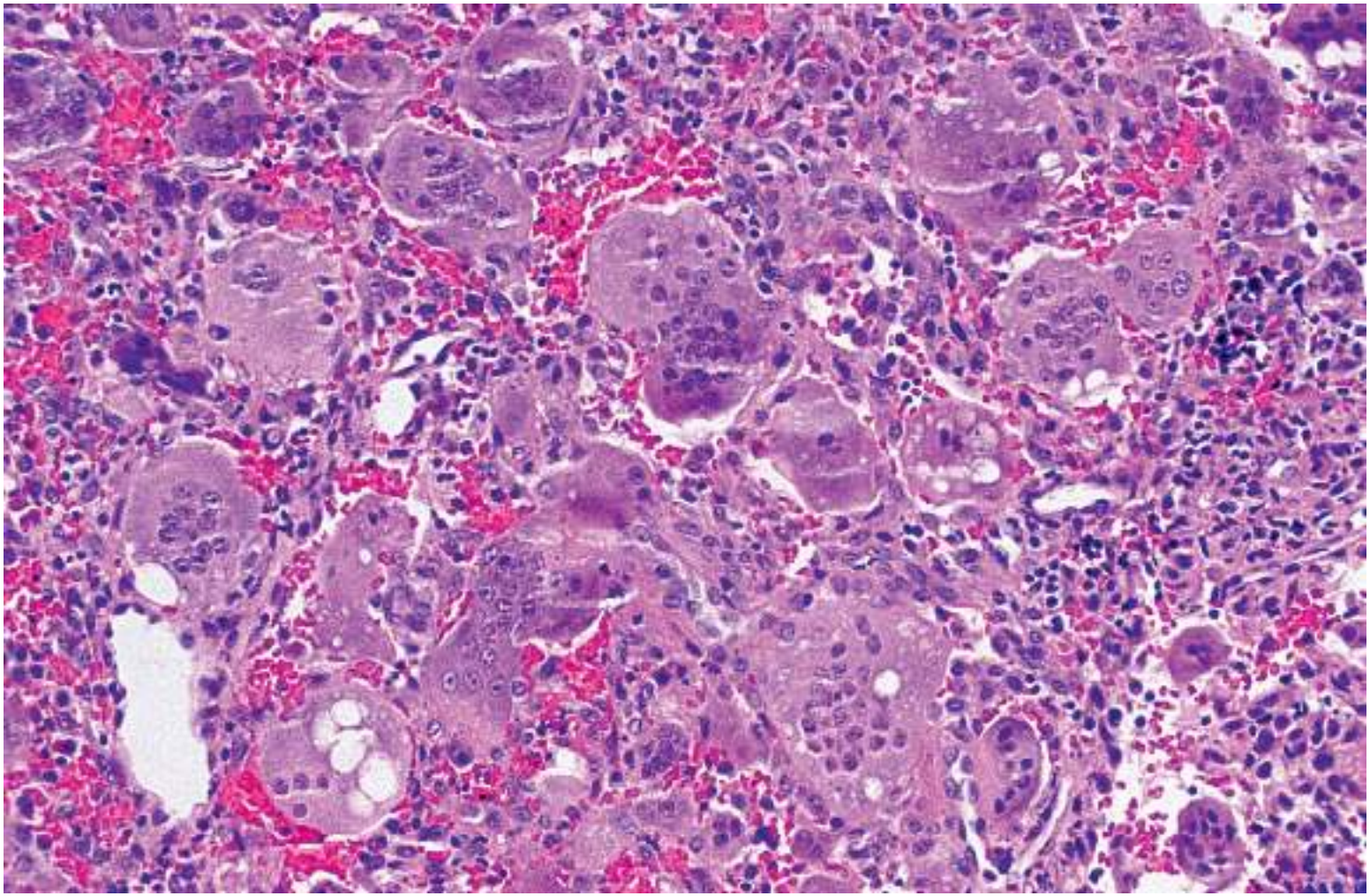

CHERUBISM

- Cherubism is a rare developmental jaw condition that is generally inherited as an autosomal dominant trait .
- The name *cherubism* was applied to this condition because the facial appearance is similar to that of the plump-cheeked little angels (cherubs),
- Although cherubism may develop as early as 1 year of age, the disease usually occurs between the ages of 2 and 5 years. In mild cases, the diagnosis may not be made until the patient reaches 10 to 12 years of age.

A

Clinical and Radiographic Features

- The clinical alterations typically progress until puberty, then stabilize and slowly regress
- The cherub like facies arises from bilateral involvement of the posterior mandible that produces angelic chubby checks.
- In addition, there is an **"eyes upturned to heaven"** appearance that is due to a wide rim of exposed sclera noted below the iris.

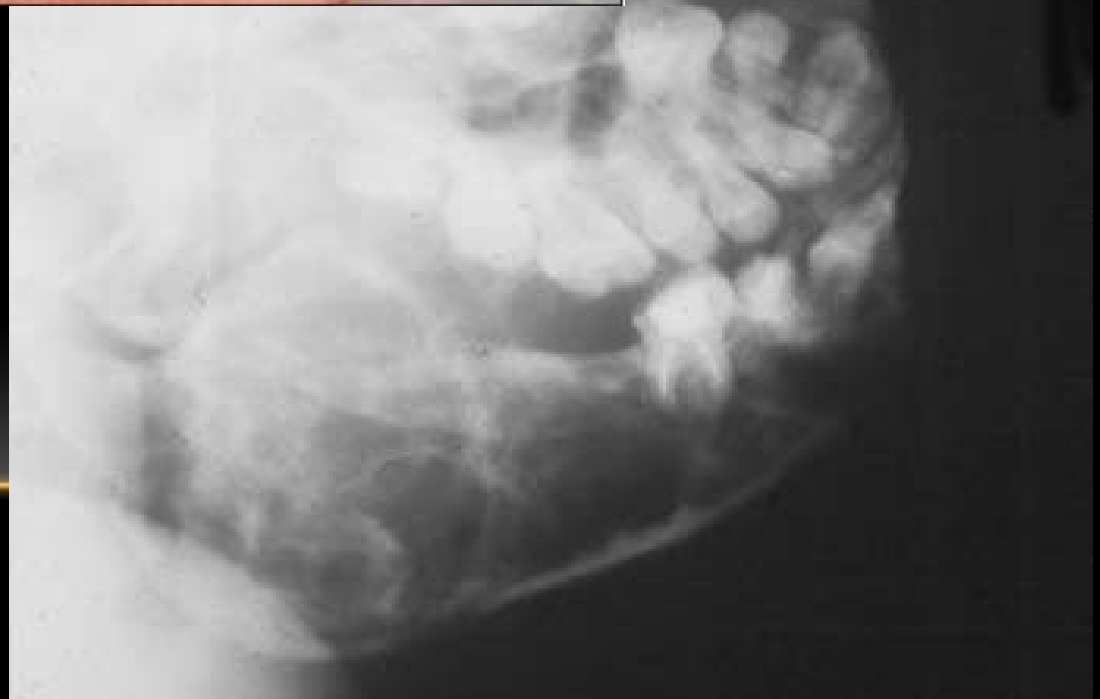

Cherubism.

A, panoramic radiograph . Bilateral multilocular radiolucencies can be seen in the posterior mandible.

B, same patient 6 years later. The lesions in the mandibular rami demonstrate significant resolution, but areas of involvement are still present in the body of the mandible.

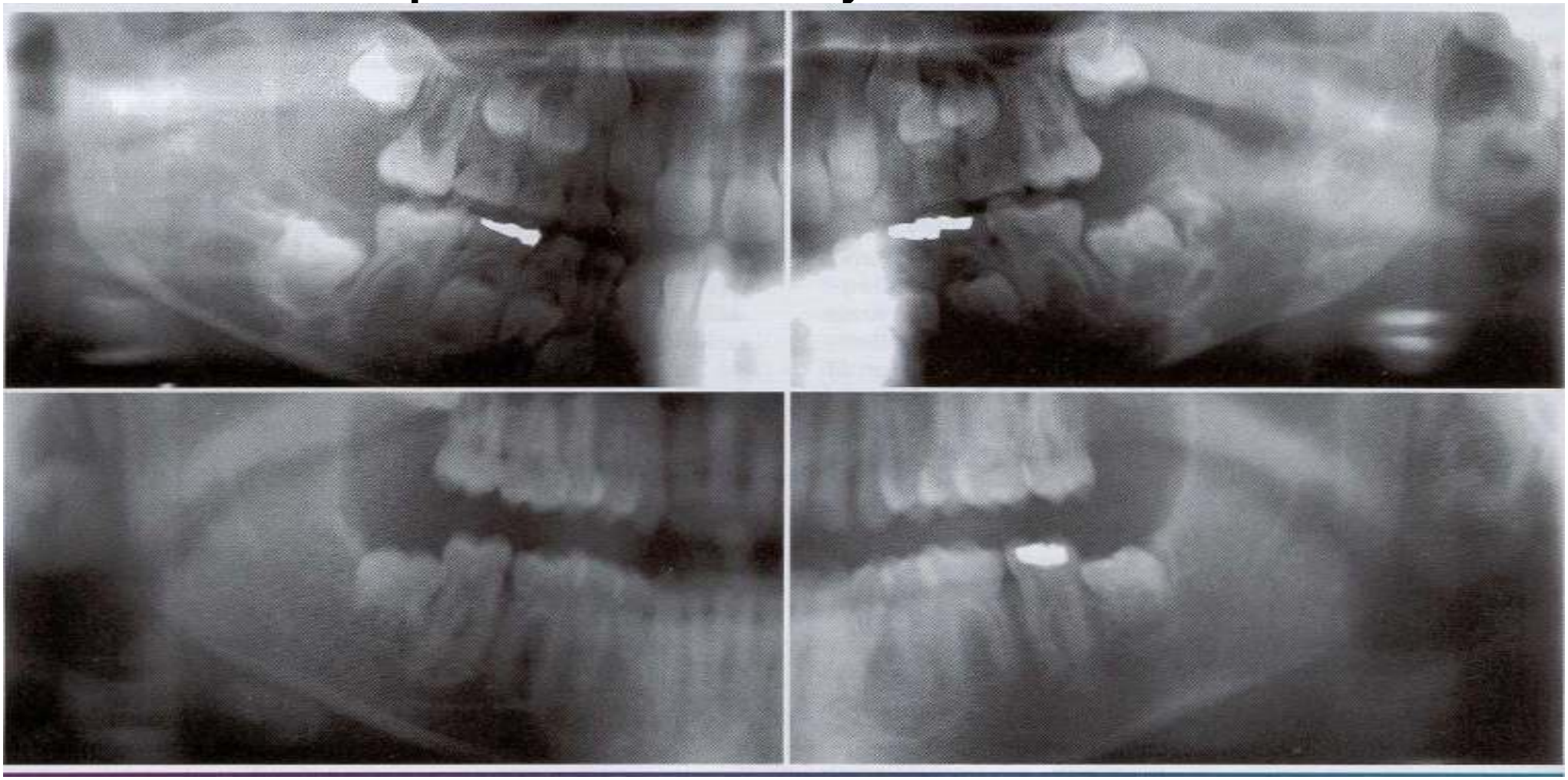

Histopathologic Features

- The microscopic findings of cherubism are essentially similar to those of isolated giant cell granulomas, and they seldom permit a specific diagnosis of cherubism in the absence of clinical and radiologic information.
- The lesional tissue consists of vascular fibrous tissue containing variable numbers of multinucleated giant cells.
- The giant cells tend to be **small** and usually **aggregated focally ,**Foci of extravasated blood are commonly present. The stroma in cherubism often tends to be more loosely arranged than that seen in giant cell granulomas.

- in some cases, cherubism reveals eosinophilic, **cuff like deposits** surrounding small blood vessels throughout the lesion. The eosinophilic cuf ﬁng appears to be specif c for cherubisrn.
- However, these deposits are not present in many cases, and their absence does not exclude a diagnosis of cherubism.
- **In older, resolving lesions of cherubism**, the tissue becomes more fibrous, the number of giant cells decreases, and new bone formation is seen.

Cherubism.

Photomicrograph showing scattered giant cells within a background of cellular, hemorrhagic mesenchymal tissue. The inset demonstrates perivascular eosinophilic cuffing.

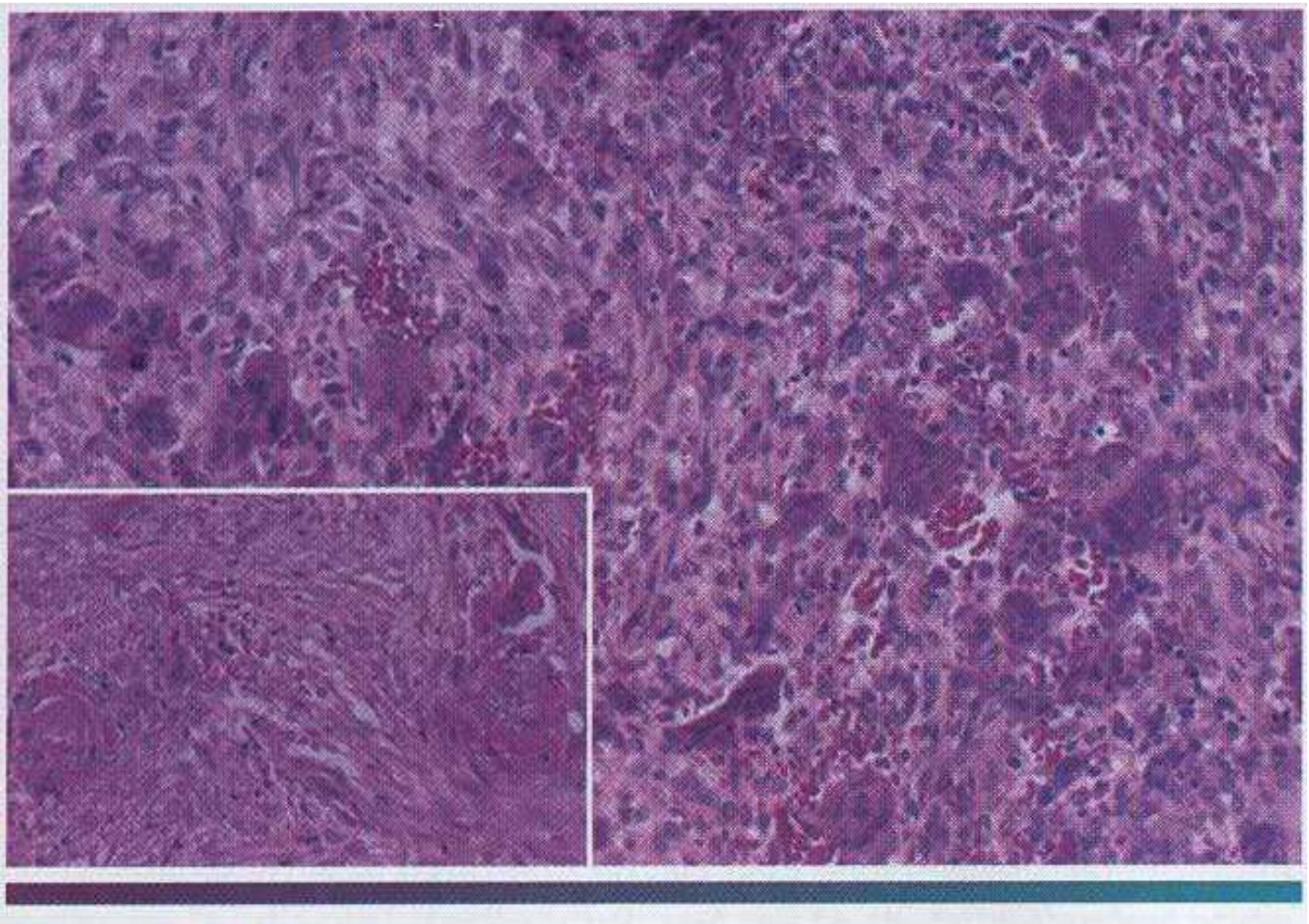

Cherubism.

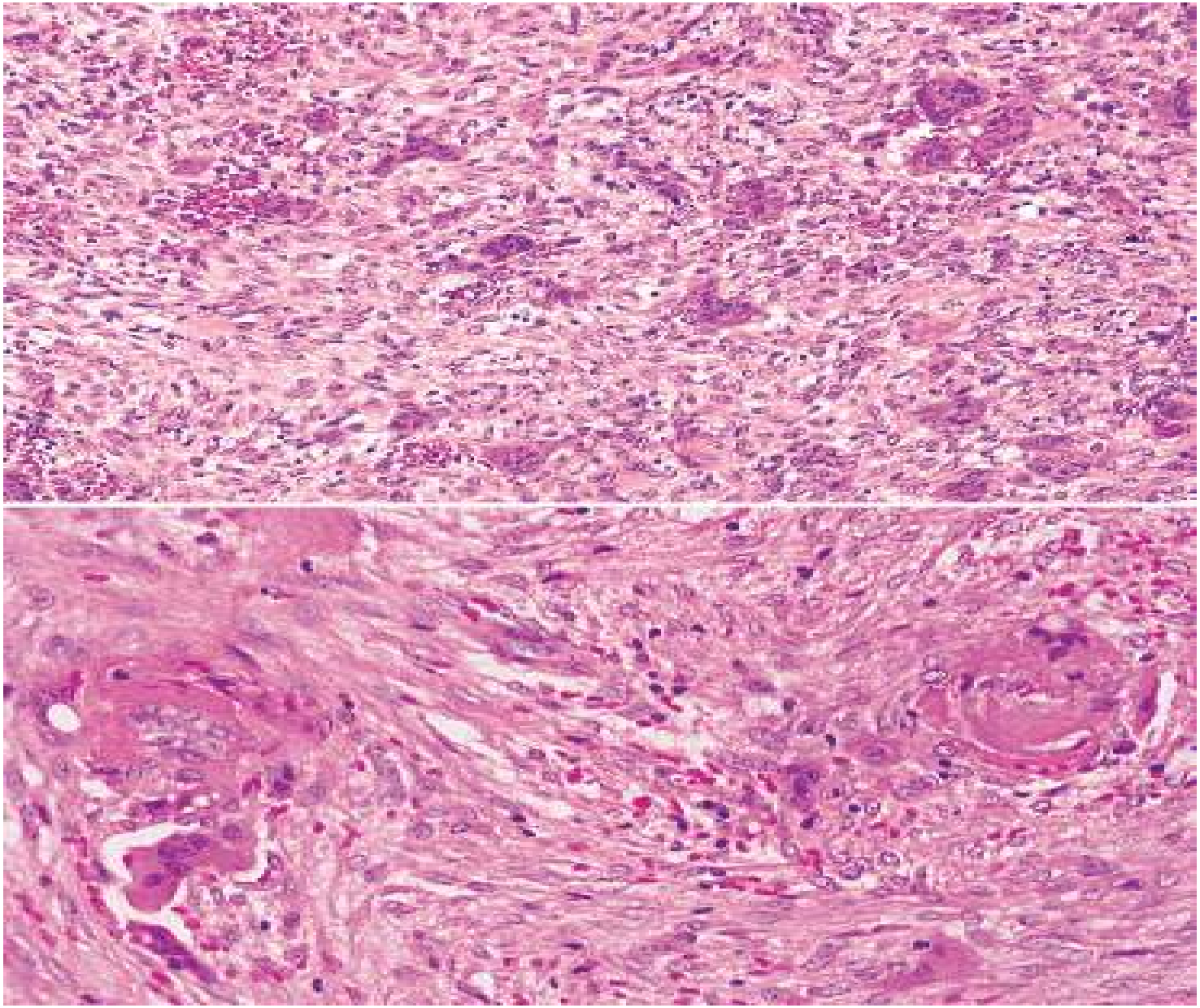

Cherubism.

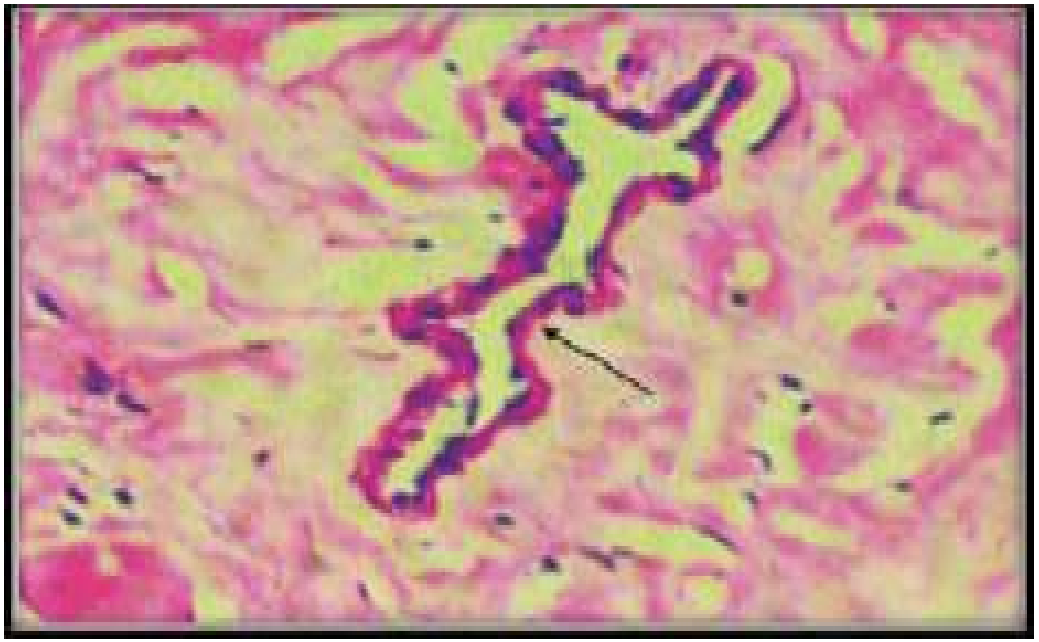

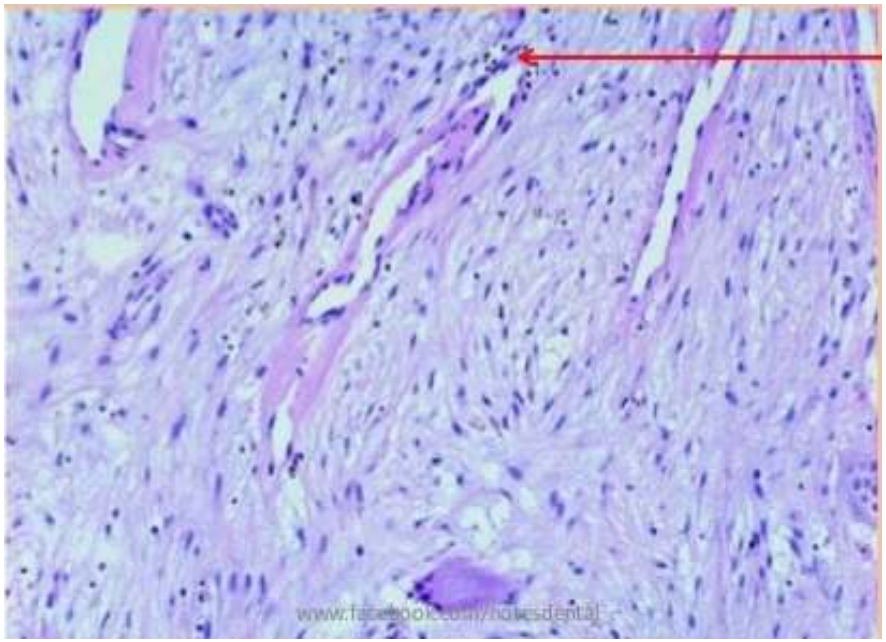

Cherubism.

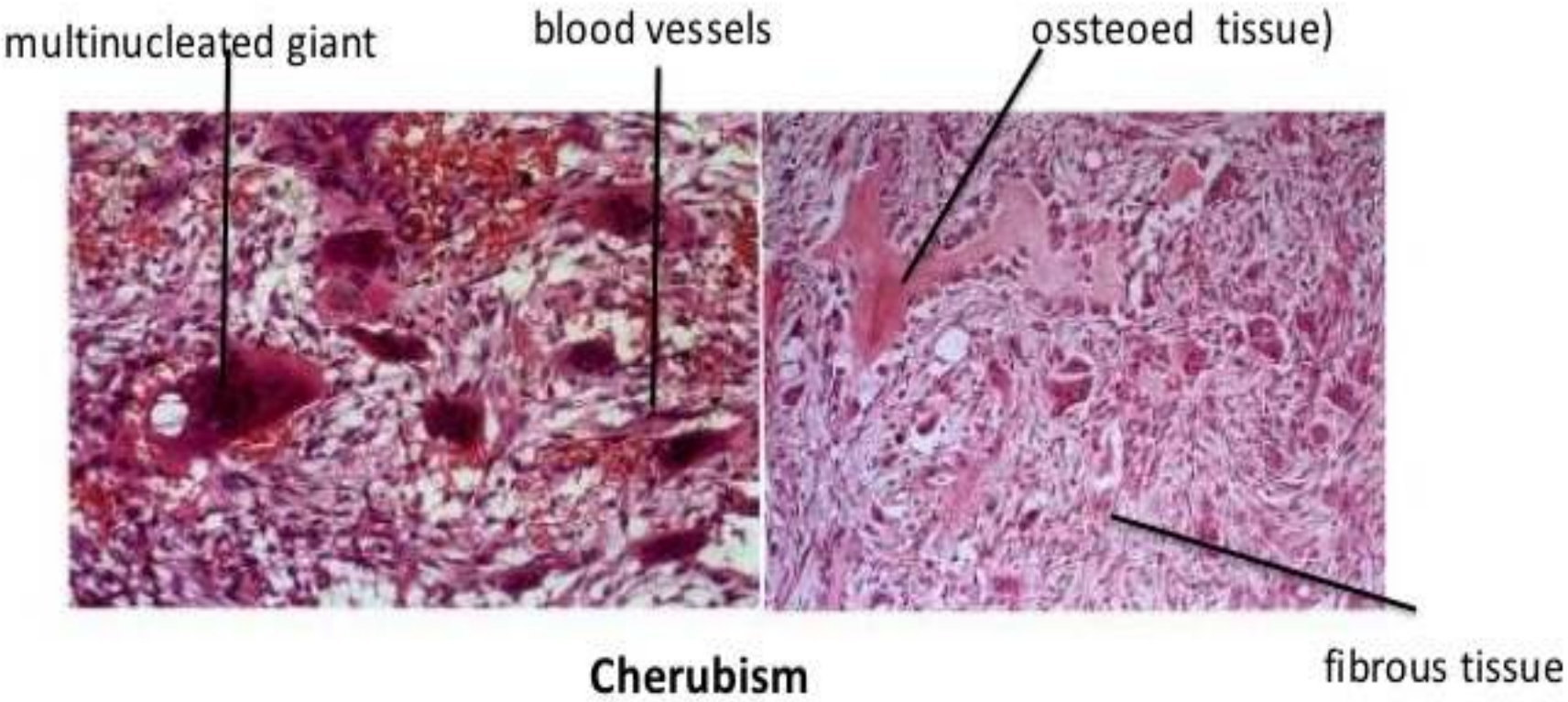

Cherubism

Aneurysmal bone cyst

- An intraosseous accumulation of variable-sized, blood-filled spaces surrounded by cellular fibrous connective tissue and reactive bone
- Because the lesion lacks an epithelial lining, it represents a pseudocyst rather than a true cyst.
- Aneurysmal bone cysts may be classified as **primary** (i.e., arising de novo) or **secondary** (i.e., arising in association with another bone lesion).

- At the time of surgery, **intact periosteum and a thin shell of bone** are typically found covering the lesion.
- Cortical perforation may occur, but spread into the adjacent soft tissue has not been documented.
- When the periosteum and bony shell are removed, dark venous blood frequently wells up and venous like bleeding may be encountered.
- The appearance at surgery has been likened to that of a "**blood-soaked sponge.**"

- Radiographic study shows a unilocular or multilocular radiolucent lesion often associated with marked cortical **expansion and thinning**.
- The radiographic borders are variable and may be well defined or diffuse.
- A ballooning or **"blow-out"** distention of the contour of the affected bone is described. Uncommonly, small radiopaque foci, thought to be small trabeculae of reactive bone, are noted within the radiolucency.

Aneurysmal bone cyst .
A large multilocular radiolucent lesion involves most of the ascending ramus in a 5-yearold white boy.

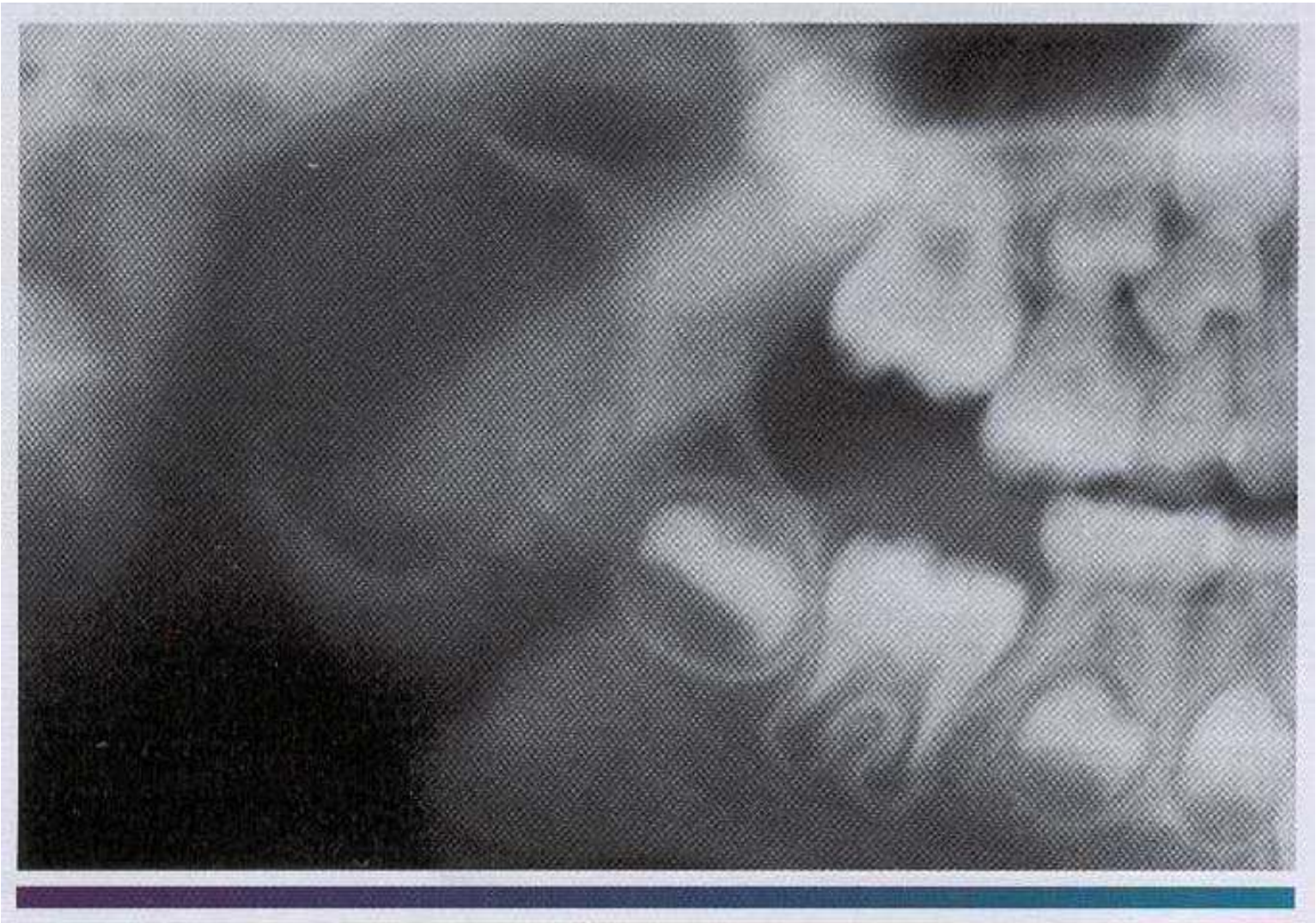

Histopathologic Features

- blood-f lled spaces lack an endothelial or epithelial lining
- The surrounding cellular f broblastic tissue contains multinucleated giant cells, osteoid, and woven bone. Similar to the multinucleated giant cells in giant cell granulomas.
- the multinucleated giant cells in aneurysmal bone cysts exhibit an osteoclastic phenotype, as evidenced by immunohistochemical study.
- Osteoid deposits may appear linear, nodular, or lacelike.
- As noted earlier, aneurysmal bone cysts may be associated with other pathoses, most commonly f bro -osseous lesions or giant cell granulomas.

Aneurysmal bone cyst.
a blood-filled space surrounded by fibroblastic connective tissue. Scattered multinucleated giant cells are seen adjacent to the vascular space.

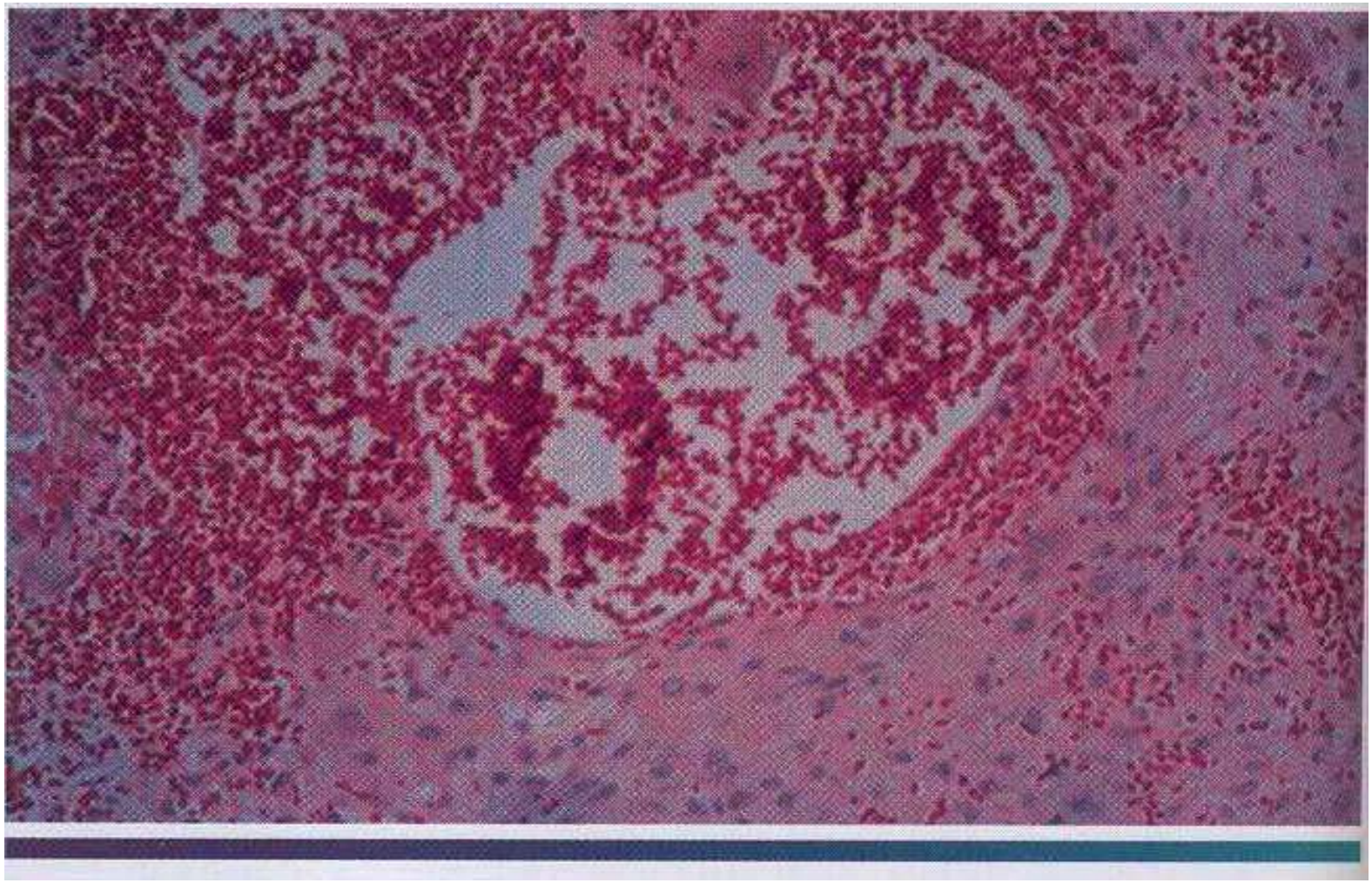

HYPERPARATHYROIDISM (Brown Tumor)

- Excess production of parathyroid hormone (PTH) results in the condition known as hyperparathyroidism. PTH normally is produced by the parathyroid glands in response to a decrease in serum calcium levels.
- Primary hyperparathyroidism is usually as a result of a parathyroid adenoma (80% to 90% of cases) or parathyroid hyperplasia (10% to 15% of cases).

- Secondary hyperparathyroidism develops when PTH is continuously produced in response to chronic low levels of serum calcium, a situation associated with chronic renal disease.
- With chronic renal disease, active vitamin D is not produced and less calcium is absorbed from the gut , resulting in lowered serum calcium levels .

Hyperparathyroidism.
This periapical radiograph reveals the "ground glass" appearance of the trabeculae and loss of lamina dura in a patient with secondary hyperparathyroidism.

- Alterations in trabecular pattern characteristically develop next A decrease in trabecular density and blurring of the normal trabecular pattern occur; often a **"ground glass"** appearance results.
- With persistent disease. other osseous lesions develop, such as the so-called **brown tumor** of hyperparathyroidism.

- **Brown tumor** derives its name from the color of the tissue specimen. which is usually a dark **reddish-brown** because of the abundant hemorrhage and hemosiderin deposition within the tumor.
- These lesions appear radiographically as well-demarcated unilocular or multilocular radiolucencies.

Hyperparathyroidism.
This occlusal radiograph of the edentulous maxillary anterior region shows a multilocular radiolucency characteristic of a brown tumor of primary hyperparathyroidism.

Hyperparathyroidism.
Palatal enlargement is characteristic of the renal osteodystrophy associated with secondary hyperparathyroidism.

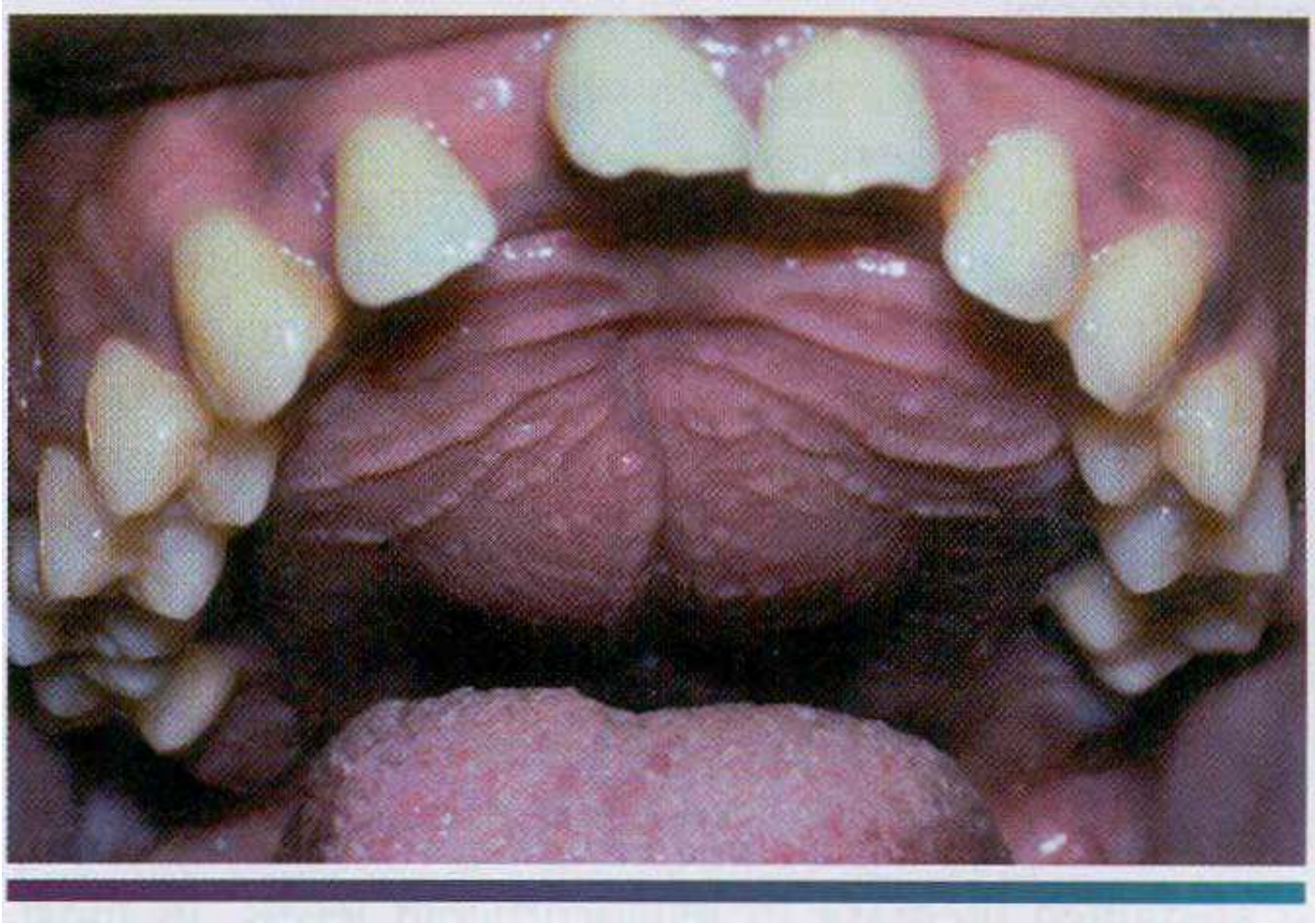

Histopathologic Features

- The brown tumor of hyperparathyroidism is histopathologically identical to the central giant cell granuloma of the jaws. Both lesions are characterized by a proliferation of exceedingly vascular granulation tissue, which serves as a background for numerous multinucleated osteoclast- type giant cells.

- Some lesions with secondary hyperparathyroidism may also show a proliferative response characterized by a parallel arrangement of spicules of woven bone set in a cellular fibroblastic background with variable numbers of multinucleated giant cells.

Hyperparathyroidism.
brown tumor of hyperparathyroidism shows scattered multinucleated giant cells within a vascular and proliferative fibroblastic background.

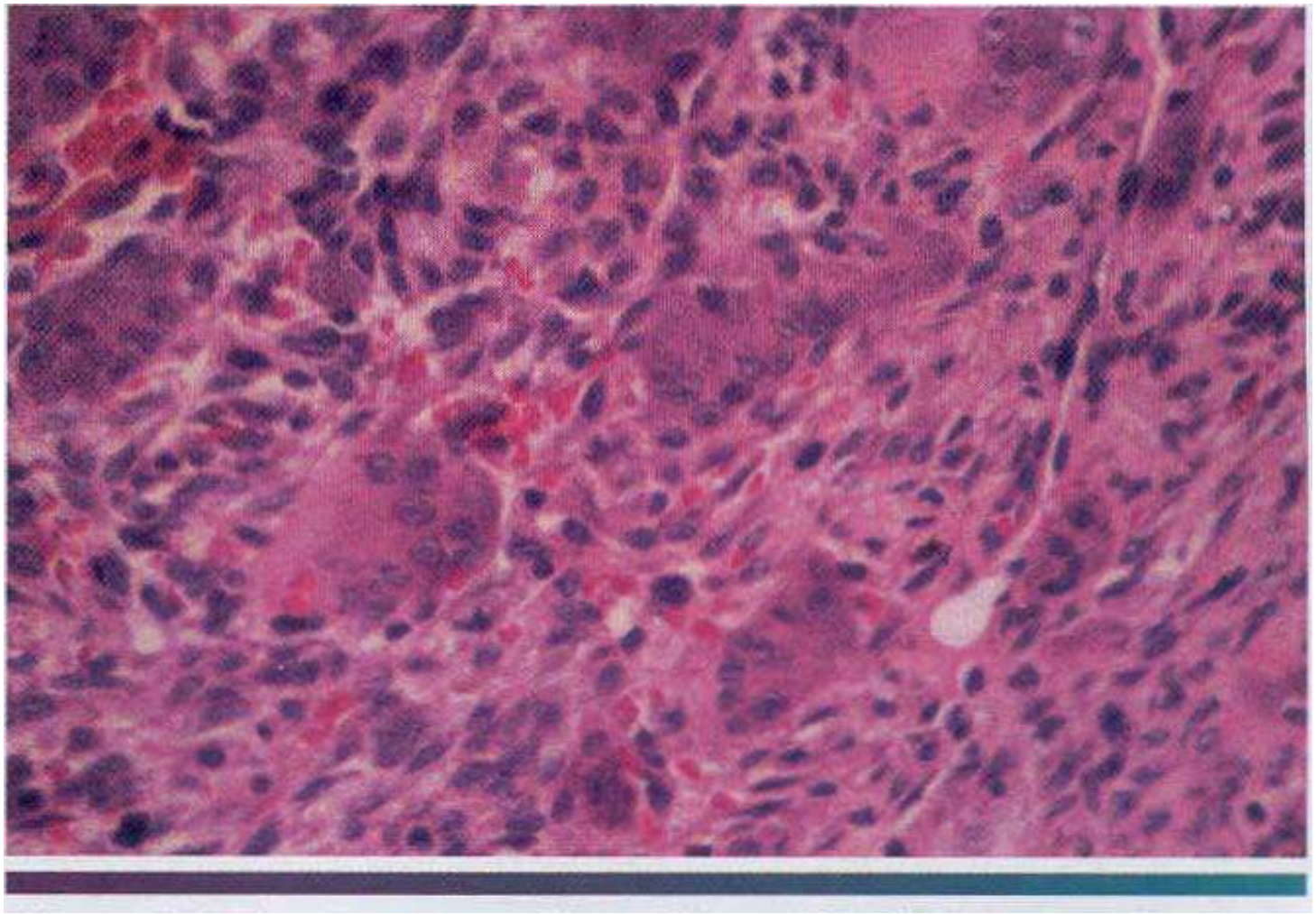
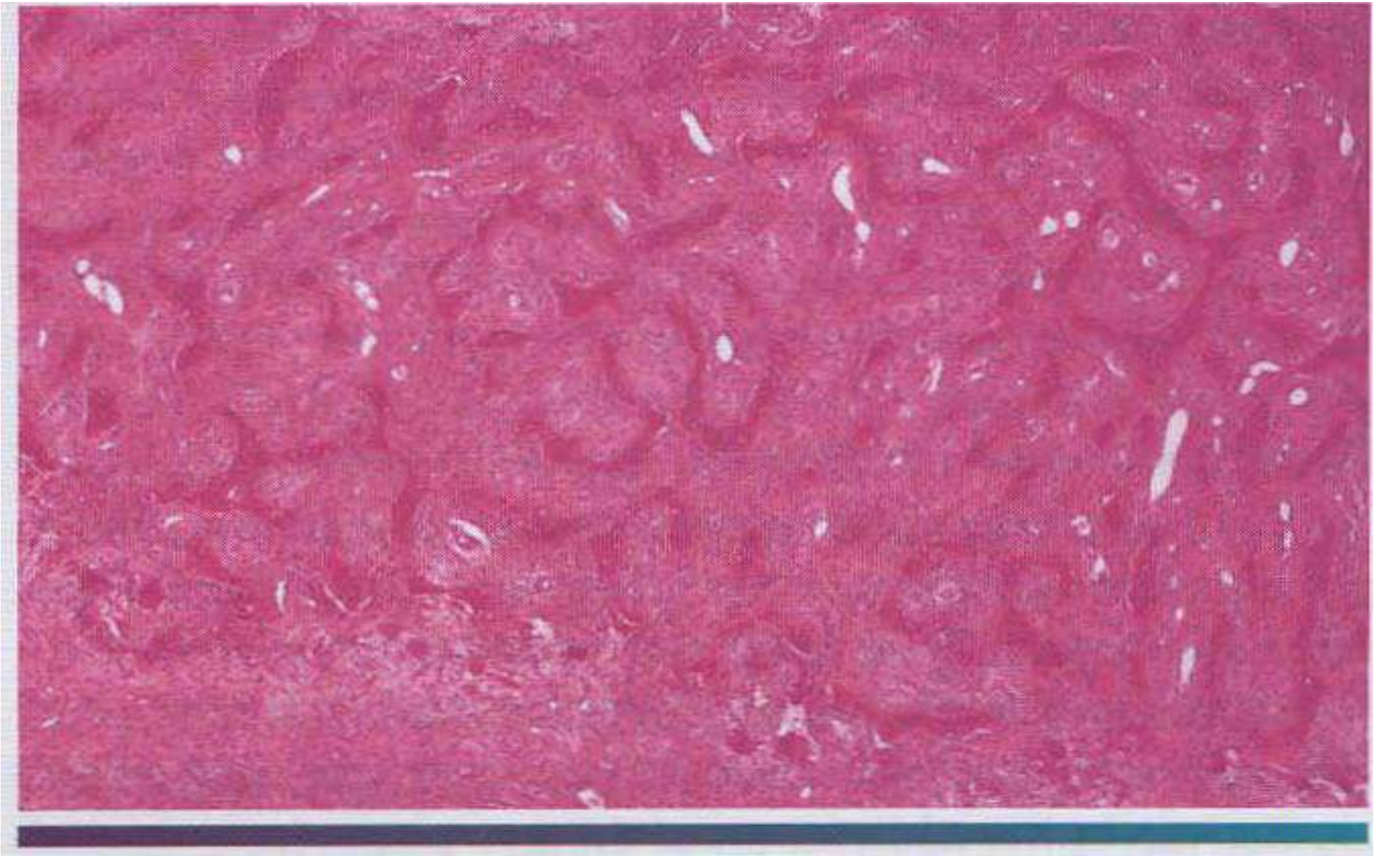
Hyperparathyroidism.
delicate, interconnecting trabeculae of woven bone within a background of cellular fibrous connective tissue.